




Contents lists available at ScienceDirect

The Journal of Foot and Ankle Surgery

journal homepage: www.elsevier.com/locate/yjfas

Original Research

Instrumented correction of metatarsus adductus with hallux valgus – A multicenter radiographic assessment

Jody Peter McAleer, DPM, FACFAS^{a,*}, Paul Dayton, DPM, MS, FACFAS^b,
Mindi Dayton, DPM, FACFAS^b, William T DeCarbo, DPM, FACFAS^c, Deidre Kile, MS^d,
Daniel J Hatch, DPM, FACFAS^e

^a Jefferson City Medical Group, Department of Podiatry, Jefferson City, MO 65109, USA^b Foot & Ankle Center of Iowa, Bunion Surgery Specialists, Ankeny, IA, USA^c Greater Pittsburgh Foot & Ankle Center, Pittsburgh, PA, USA^d Actalent, Hanover, MD, USA^e Foot and Ankle Center of the Rockies, Greeley, CO, USA

ARTICLE INFO

Keywords:

Plumline

Sgarlato's angle

Tarsometatarsal

Arthrodesis

Triplanar

ABSTRACT

Failure to address metatarsus adductus (MTA) with coexisting hallux valgus (HV) has resulted in mixed outcomes and increased deformity recurrence. The purpose of this study was to investigate early radiographic and clinical outcomes of a novel instrumented 2nd and 3rd TMT corrective arthrodesis combined with instrumented triplanar 1st TMT arthrodesis with early weightbearing. Radiographs and medical records from subjects undergoing this surgical approach were retrospectively reviewed. Forty-three subjects (N = 43 feet) with a mean \pm SD age of 41.6 ± 14.2 (range 15 to 62) years were treated at four institutions with a mean \pm SD follow-up time of 17.7 ± 10.6 (range 11.5 to 51.0) months. Radiographic parameters demonstrated improvements in the mean \pm SD Sgarlato's angle (26.3 ± 5.7 to 10.2 ± 3.8 degrees), baseline 'True Intermetatarsal Angle' (23.2 ± 6.6 degrees) to measured Intermetatarsal Angle at final follow-up (3.7 ± 2.4 degrees), Hallux Valgus Angle (32.3 ± 8.4 to 7.2 ± 6.6 degrees), Tibial Sesamoid Position (5.0 ± 1.5 to 1.3 ± 1.1) and Osseous Foot Width (97.8 ± 7.0 to 86.8 ± 7.5 mm). The novel baseline Plumline measurement was 93.0 % positive in the study cohort and converted to a negative reading following MTA correction in 90.7 % of subjects. All (N = 43) feet studied achieved stable arthrodesis at the time of final clinical and radiographic assessment. One patient required hardware removal. Radiographic outcomes of an instrumented triplanar correction and multi-planar locking plate fixation were promising with correction of the MTA and HV deformities and favorable healing noted.

Level of evidence: Level 4, case series

Introduction

Metatarsus adductus (MTA) is a congenital foot deformity present in 0.1 % of the population with a ~30 % incidence in individuals with hallux valgus (HV), highlighting the commonality and interrelation [1]. Early observations suggest MTA has a purely transverse plane forefoot malalignment, but recent opinions suggest a triplanar tarsometatarsal (TMT) origin with hindfoot influence [2–4]. Clinical features include a wide forefoot, concavity of the medial foot, and a fibular deviation of the digits at the metatarsophalangeal (MTP) joints.

Isolated HV correction has inconsistent outcomes when MTA is

present [5,6]. Failure to address MTA has been reported to result in a 30 % radiographic recurrence of HV [1]. A retrospective study of 15 subjects undergoing isolated HV surgery with MTA present indicated a 40 % patient dissatisfaction with a "striking under-correction" [4]. Malalignment of the lesser metatarsals hinders surgical positioning of the first resulting in residual deformity, HV recurrence, and increased post-operative pain [5]. VAS and FAOS outcome scores have also been negatively impacted in subjects having undergone isolated HV surgery without addressing the MTA [6].

Procedures addressing MTA have been described but with inconsistent results [7–10]. Second and third TMT joint realignment arthrodesis

* Corresponding author.

E-mail addresses: jmcaleer@jcmg.org (J.P. McAleer), daytonp@icloud.com (P. Dayton), mindi.dayton@icloud.com (M. Dayton), wdecarbo@yahoo.com (W.T. DeCarbo), dkile@actalentservices.com (D. Kile), dhatch@fackrockies.com (D.J. Hatch).

<https://doi.org/10.1053/j.jfas.2025.03.001>

Available online 7 March 2025

1067-2516/© 2025 The Author(s). This is an open access article under the CC BY-NC-ND license (<http://creativecommons.org/licenses/by-nc-nd/4.0/>).

has been reported to yield acceptable outcomes and creates space for first ray correction [11]; however, freehanded approaches may introduce an unpredictable degree of variability. The purpose of this study is to investigate radiographic and clinical outcomes of an instrumented triplane corrective joint arthrodesis of the third, second, and first TMT (3/2/1) for MTA with HV. We hope to show that this approach provides midfoot stability, realigns the central rays, uncovers the 'True intermetatarsal angle' (IMA), creates space for first ray realignment, and may reduce the incidence of HV recurrence [12,13].

Patients & Methods

Upon receipt of an institutional review board (IRB) exemption, an electronic health record query using common procedural coding (28740, 28730, 28735) was carried out to identify potential subjects. Pertinent data was imputed into a secure shared database (Quickbase, Boston, MA). Subjects at four institutions were identified who underwent an instrumented 3/2/1 TMT corrective arthrodesis for MTA/HV performed by five Diplomates of the American Board of Foot and Ankle Surgery, each with 20+ years of experience (JM, MD, PD, WD, DH). An instrumented system recently described in the literature reliant on a standardized technique was utilized for all subjects [14]. (Treace Medical Concepts, Ponte Vedra, FL). A contiguous closing wedge cut of the second and third TMT was completed to correct the rays as one unit while maintaining key soft tissue attachments. The lesser TMT cut guide was developed based on a similar freehand technique that the authors employed before the instrumented system was introduced [Fig 1a and 1b]. Fenestration of the cut bone surfaces was performed. The corrected foot position was then completed through abduction, frontal plane pronation and slight dorsiflexion of the lesser metatarsals in an "up and out" motion [15] [Fig 2]. The fourth and fifth TMT joints did not require soft tissue release, osteotomy or fusion, and lateral column correction was obtained through manual manipulation of the metatarsals. Fixed angle locking plates and screws were placed along the midline anatomic contours of the second and third TMT joints to maximize direct bone contact to and promote healing. The positional correction of the second and third ray to the longitudinal foot axis uncovered the 'True IMA' radiographically [16,17] [Fig 3]. The first ray was subsequently corrected in three-dimensions and secured via arthrodesis. The construct utilized a low-profile fixed angle locking titanium plate/screw system with two plates orientated ~90 degrees apart at the first TMT. [Fig 4a and 4b] This provides stability while maintaining the capacity for physiologic micromotion to promote callus healing [18]. Adjunctive

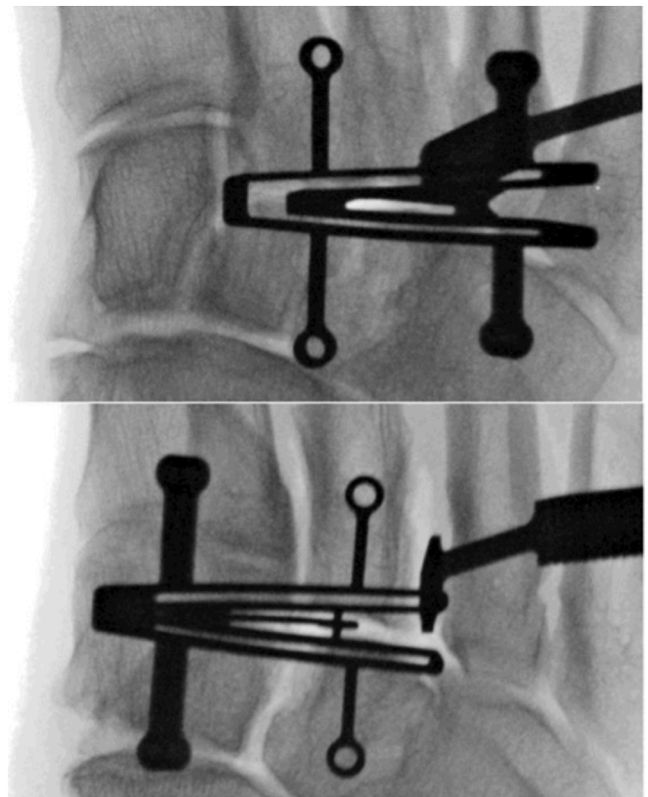


Figure 1b. Radiographic appearance of cut guide over second (top) and third (bottom) tarsometatarsal joints.

surgical procedures were recorded including supplemental midfoot stabilization screw placement if excessive transverse plane instability was observed. Protected weightbearing and low-impact activities were permitted on the surgical limb when donning a controlled ankle motion (CAM) boot. A transition to athletic shoes was encouraged at week six, with a return to more strenuous activity when clinically and radiographically stable.

Subjects were considered for inclusion if clinical and radiographic follow-up were available at baseline and a minimum of 12 months post-operative. Inclusion required the baseline presence of MTA with a

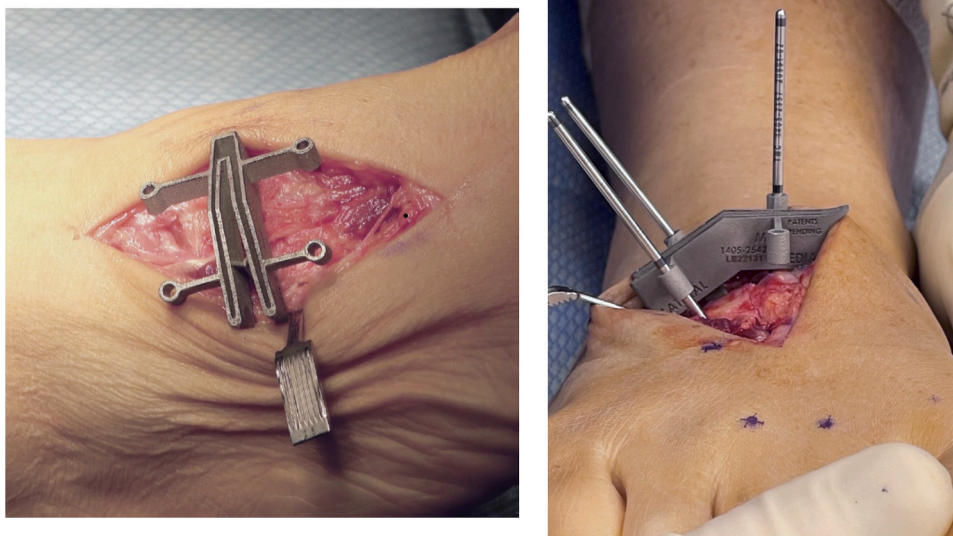


Figure 1a. Clinical appearance of metatarsus adductus cut guide.

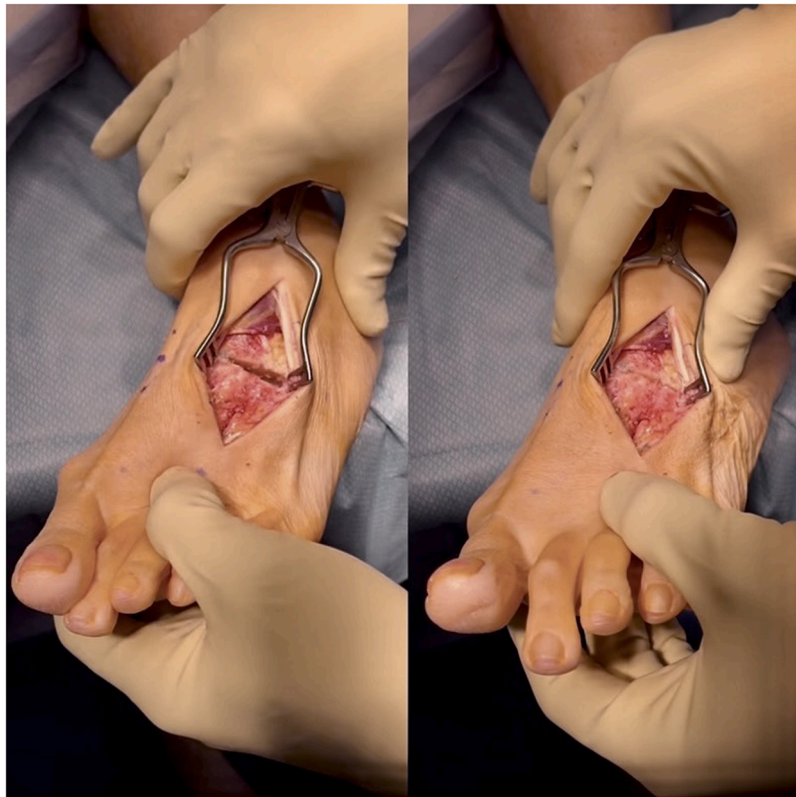

Figure 2. “Up and out” maneuver reducing the lesser metatarsal position following tarsometatarsal osteotomy. In this case the left hand will dorsiflex and evert while the right hand applies counter pressure.

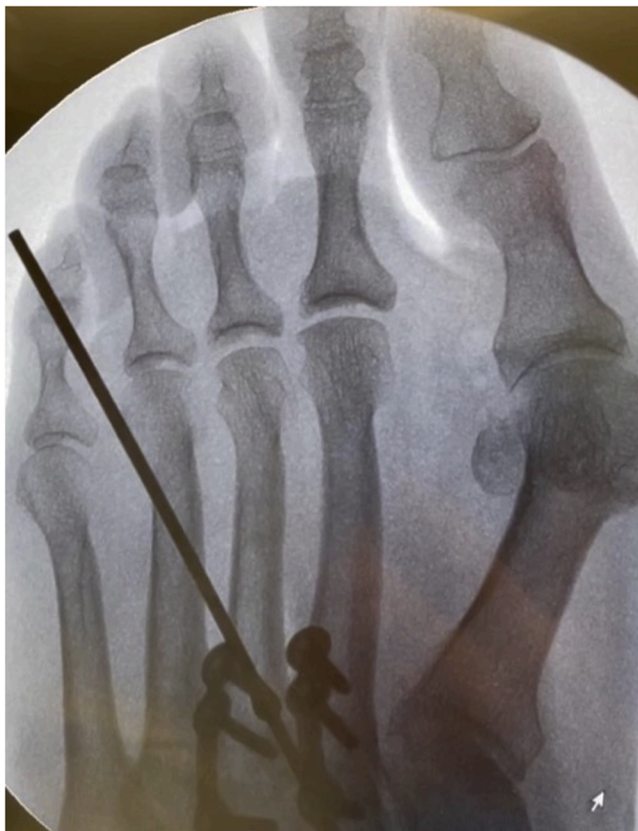

Figure 3. ‘True intermetatarsal angle’ revealed following angular correction of lesser metatarsals.

Sgarlato’s angle (SA) $>15^\circ$, IMA $> 10^\circ$ and/or hallux valgus angle (HVA) $>15^\circ$, and surgeon-identified indications for corrective arthrodesis. Baseline exclusion criteria included revision of failed procedures, previous infection of the operative foot, MTP degenerative joint disease, neuropathy, and concomitant hindfoot or ankle procedures with an exemption for gastrocnemius recession.

Radiographic measures were completed using a digital radiographic viewing system at each facility. The comparison of baseline and post-operative weightbearing plain film radiographs included the assessment of HVA, IMA, SA, Plumline (PL), tibial sesamoid position (TSP), osseous foot width (OFW), ‘True IMA’ and healing of the arthrodesis sites. HVA was defined as the angle between the longitudinal axis of the first metatarsal and proximal phalanx. IMA was defined as the angle between the longitudinal axes of the first and second metatarsals. The SA was defined by marking tangential reference lines from the first metatarsal cuneiform joint to the proximal navicular and from the distal and proximal cuboid articulations [19]. The reference line midpoints were linked with a line crossing the midfoot. A line 90 degrees from the midfoot reference line is compared to a longitudinal bisection of the second metatarsal creating the SA [Fig 5a]. A novel measurement known as the PL was also used to assess the presence of MTA [20]. A cuneiform axis line was identified by linking two individual points marked at the medial first TMT joint and the medial naviculo-cuneiform (NC) joint [21]. A third point was marked at the lateral first TMT joint. The cuneiform axis line was translated in a parallel fashion to the third point at the lateral first TMT joint. This PL was extended distally to the level of the second metatarsal head. [Fig 5b] If this line intersected the second metatarsal head, it was considered positive and indicated the presence of MTA. TSP was graded from 1 to 7 and defined as the position of the medial sesamoid in relation to the longitudinal axis of the first metatarsal [22,23]. OFW was determined by measuring a line which extends from the farthest bone projection of the first and fifth metatarsal heads [24]. The pre-operative ‘True IMA’ measurement was determined using

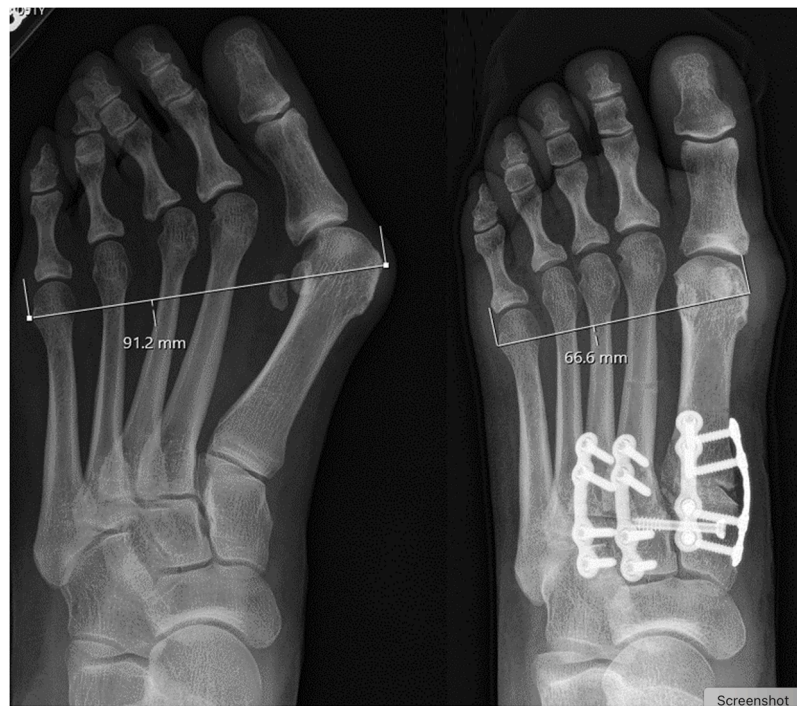


Figure 4a. Pre-operative (left) and post-operative (right) anteroposterior plain films depicting a reduction of osseous foot width, metatarsus adductus angle, Intermetatarsal angle, 'true intermetatarsal angle and hallux valgus angle.

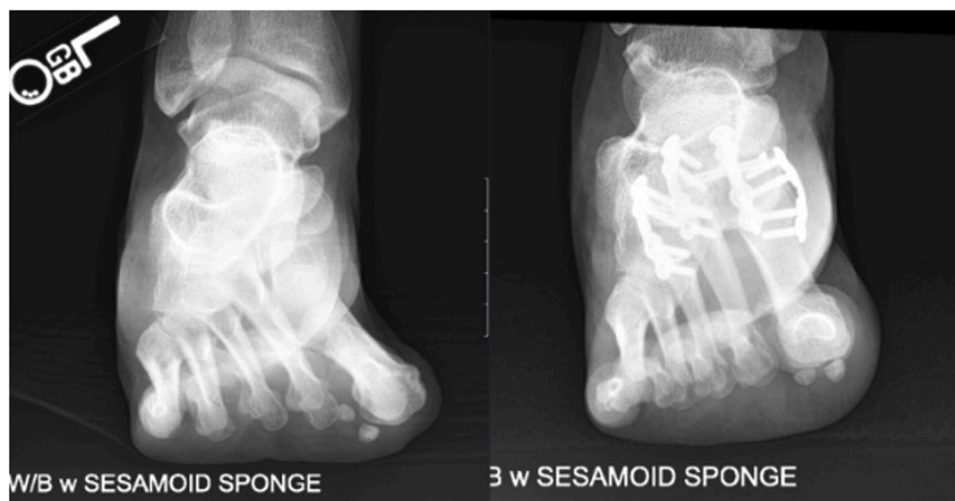

Figure 4b. Pre-operative (left) and post-operative (right) sesamoid axial plain films depicting a reduction in tibial sesamoid position.

the calculation $TRUE\ IMA = IMA + (SA - 15^\circ)$ [13,25]. Radiographic images from baseline and last point of follow-up were analyzed by the authors and no inter-observer measurement discrepancies were identified.

Radiographic TMT nonunion included the presence of any of the following at final imaging: 1) lack of progressive TMT joint osseous density; 2) hardware failure (broken plate/screws) or loosening (halos around screws); 3) loss of radiographic correction. The clinical definition included persistent pain and TMT motion at final follow-up and had to correlate with radiographic findings defining non-union.

Baseline and final post-operative clinical examination included assessment of MTP/TMT joint pain and joint swelling/crepitus. Interval postoperative observations included the return to protected weight-bearing, athletic shoes and full activity. Complications were recorded including delayed healing, infection, hardware removal, non-union or

surgical revision. Demographic data collection included age, gender, surgical laterality, smoking status, relevant comorbidities, associated foot deformities, and any history of previous surgery on the operative foot.

Statistical analysis of the study data was performed by an experienced contracted biostatistician. There is no formal sample size calculation as this is a single arm study that is primarily descriptive in nature. All analyses were based on available data, without imputation for missing values. All continuous variables were summarized using the following descriptive statistics: n, mean, standard deviation (SD), median, minimum, maximum. The frequency and percentages of observed levels were reported for all categorical measures. All analyses were conducted using SAS version 9.4 (SAS Institute Inc., Cary, NC).

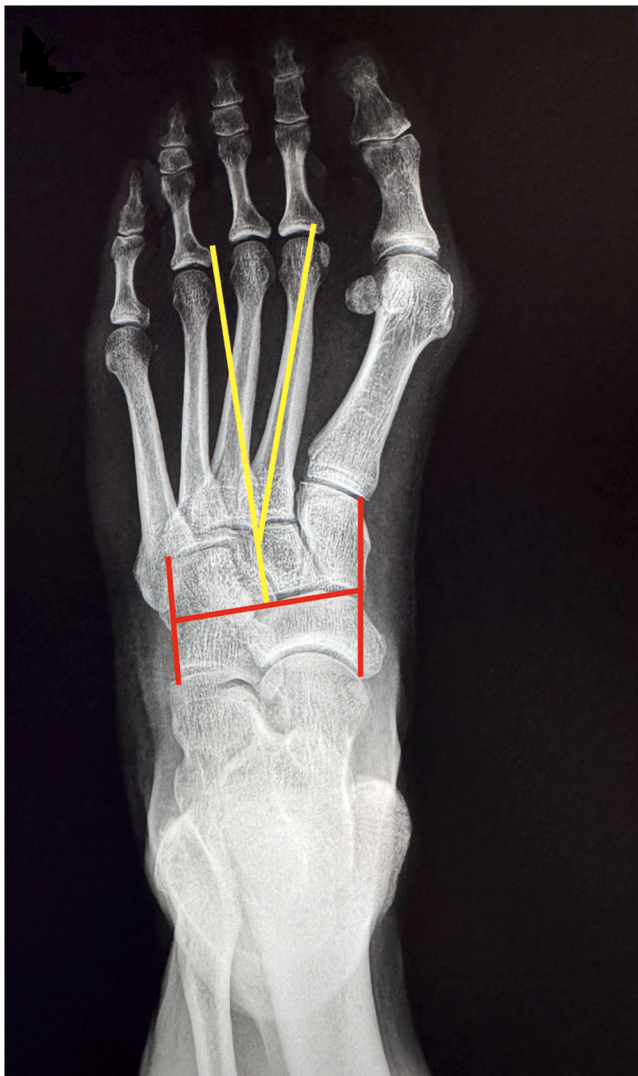

Figure 5a. Metatarsus adductus angle measurement using Sgarlato's Angle.

Results

Forty-three subjects (81.4 % female) with a mean \pm SD age of 41.6 ± 14.2 (range 15 to 62) years were identified having undergone an instrumented 3/2/1 TMT corrective arthrodesis for MTA/HV. Seventeen (39.5 %) were right foot procedures. Mean \pm SD time to final radiographic exam was 17.7 ± 10.6 (range 11.5 to 51.0) months. Subjects were healthy with no lower extremity complications of diabetes or other manifestations of systemic disease reported. Two (4.7 %) subjects were current nicotine users [Table 1]. Fifteen (34.9 %) subjects had degenerative TMT joint changes; however, our TMT arthrodesis indication was based solely on the concept of deformity correction at the apex [Table 1]. Subjects began protected weightbearing in a tall CAM boot within a mean \pm SD of 11.2 ± 16.3 (range 0.0 to 54.0) days. Mean \pm SD time to weightbearing in athletic shoes was 55.0 ± 16.4 (range 31.0 to 94.0) days and mean \pm SD time to unrestricted activity was 110.8 ± 26.6 (range 70.0 to 198.0) days.

Thirty-eight (88.3 %) subjects reported pain under the first, second, or third MTP at baseline with one subject reporting metatarsalgia at final follow-up. Fourteen (32.6 %) subjects had concomitant procedure(s) performed during the index procedure. Twelve (27.9 %) had calcaneal autograft placed at the fusion sites and, of these, three had an Akin osteotomy and one had hammertoe correction. Two (4.7 %) subjects had hammertoe correction only. Ten subjects (23.3 %) had a supplemental

C1-C2 screw placed. Seven (16.3 %) subjects participated in physical therapy.

Radiographic parameters demonstrated improvements in the mean \pm SD SA (26.3 ± 5.7 to 10.2 ± 3.8 degrees), baseline 'True IMA' (23.2 ± 6.6 degrees) to measured IMA at final follow-up (3.7 ± 2.4 degrees), HVA (32.3 ± 8.4 to 7.2 ± 6.6 degrees), TSP (5.0 ± 1.5 to 1.3 ± 1.1) and OFW (97.8 ± 7.0 to 86.8 ± 7.5 mm) [Fig 6]. At baseline, the novel PL measurement was 93.0 % positive in the study cohort and converted to a negative reading following MTA correction in 90.7 % of subjects [Table 2]. We also observed that the use of the novel PL measurement accurately predicted the absence of MTA in 97.7 % of subjects at the time of final follow-up. Anecdotally, we observed a SA reduction of >50 % following operative correction in 35 of 43 subjects (81.4 %).

Seven (16.3 %) of the subjects had a faint lucency at the second and/or third TMT joint at final radiographic follow-up, two of whom had a broken screw. However, these subjects were clinically asymptomatic and met our criteria for stable and progressively healing arthrodesis of the TMT joints at a mean follow-up of 17.7 months.

Two subjects developed post-operative complications. One developed a wound complication which resolved with treatment but delayed weightbearing progression to prevent further complication. Another developed a minor soft tissue infection that resolved with treatment and had no bearing on activity progression or healing.

Discussion

This case series depicts consistent radiographic reduction of osseous forefoot width and angle measurements using an instrumented triplane 3/2/1 TMT corrective joint arthrodesis. Bone healing complications and correction loss were not common, even with an early return to protected weightbearing. This approach produced a reduction in HVA, IMA, SA, PL, TSP, OFW and uncovered the 'True IMA'. The metatarsals are realigned using a triplanar "up and out" technique following bone slice removal. This corrects all planar components concurrently with consistent radiographic reduction of the SA and normalization of the PL. The instrumented MTA correction makes the intra-operative IMA equivalent to the calculated baseline 'True IMA'. The second and third TMT have minimal native motion and corrective arthrodesis fits with our concept of treating the deformity nearest to its apex and did not produce a stiff or painful foot for subjects [26,27]. The repositioned lesser metatarsal position helps determine the amount of room available for first ray realignment. The first metatarsal, hallux and sesamoid position are then reduced using an instrumented technique. The improvement in TSP is achieved following a combination of lateral MTP soft tissue release and first metatarsal inversion which reduces the risk of HV recurrence [28,29].

A painless great toe, correction of footwear problems, and improved walking are reported as important factors influencing outcomes [30]. This technique has a notable effect on OFW which plays a major role in pain abatement when wearing shoes [31,32]. Addressing MTA with rotational and translational osteotomies of the lesser metatarsals has been described but may result in osseous deformity and can produce metatarsalgia due to metatarsal elevation along the weightbearing parabola [4,33]. Corrective 3/2/1 TMT joint arthrodesis maintained the metatarsal parabola, realigned metatarsal position, and resolved metatarsalgia in subjects reporting symptoms at baseline. The range of motion of the fourth and fifth TMT is leveraged to manipulate and correct the lateral column without the need for additional procedures [34].

Several MTA radiographic measurement techniques have been described with SA having been reported to have the highest intra-observer and interobserver reliability with a SA $>15^\circ$ typically accepted as abnormal [1,12]. However, a pathologic range of $10-20^\circ$ has been described in the literature which clouds the value of the measurement and its relevance in surgical decision making [5]. We did not seek to establish a normal range for SA or confirm or refute previous published data. For the purposes of this study, we maintained a SA of $>15^\circ$ as the

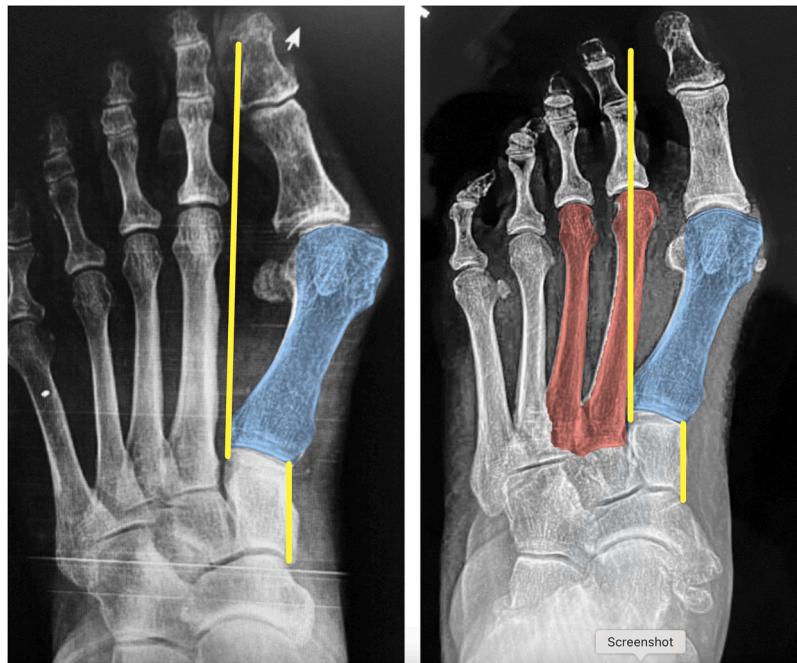


Figure 5b. Assessment of the absence (left) and presence (right) of metatarsus adductus using the Plumbline.

Table 1

Baseline Demographics and Medical/Surgical History (N = 43).

Characteristic	All Treated Subjects (N = 43)
Age (yr), Mean (SD)	41.6 (14.2)
Gender (Female)	35 (81.4 %)
Nicotine User	2 (4.7 %)
Diabetic	1 (2.3 %)
Peripheral Neuropathy = No	43 (100 %)
1st/2nd/3rd TMT Osteoarthritis	15 (34.9 %)

Table 2

Pre-operative & Post-operative Radiographic Values (N = 43).

Radiographic Measurements	Baseline (N = 43)	Final Follow-Up (N = 43)	Change from Baseline (N = 43)
Hallux Valgus Angle (°)			
Mean (SD)	32.3 (8.4)	7.2 (6.6)	-25.2 (8.9)
Median (Min, Max)	33.1 (11.5, 51.5)	6.2 (-2.5, 27.0)	-26.2 (-49.7, -3.4)
Intermetatarsal Angle (°)			
Mean (SD)	12.0 (3.0)	3.7 (2.4)	-8.2 (3.5)
Median (Min, Max)	12.1 (6.0, 19.9)	3.4 (0.0, 9.0)	-8.2 (-16.0, -0.6)
Tibial Sesamoid Position			
Mean (SD)	5.0 (1.5)	1.3 (1.1)	-3.6 (1.4)
Median (Min, Max)	5.0 (2.0, 7.0)	1.0 (0.0, 4.0)	-4.0 (-7.0, -1.0)
Sgarlato's Angle (°)			
Mean (SD)	26.3 (5.7)	10.2 (3.8)	-16.1 (4.5)
Median (Min, Max)	26.5 (14.2, 41.0)	10.7 (2.4, 22.8)	-16.8 (-29.0, -7.5)
Plumbline (±)			
Positive	Positive	Positive	1 (2.3 %)
Negative	Negative	Negative	39 (90.7 %)
True Intermetatarsal Angle (°)			
Mean (SD)	23.2 (6.6)	-1.0 (4.2)	-24.3 (6.4)
Median (Min, Max)	23.0 (11.6, 39.6)	-1.0 (-12.0, 9.4)	-24.4 (-39.9, -13.7)
Oseous Foot Width (mm)			
Mean (SD)	97.8 (7.0)	86.8 (7.5)	-11.0 (3.5)
Median (Min, Max)	98.0 (82.5, 114.4)	86.3 (72.0, 102.7)	-10.3 (-18.8, -5.4)

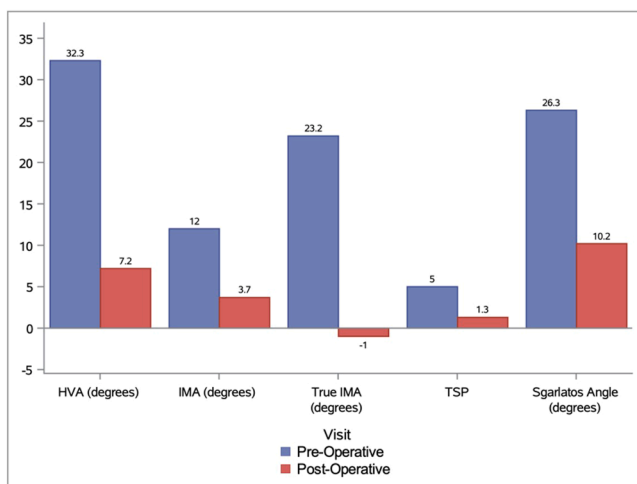


Figure 6. Changes in radiographic measurements from baseline to final follow-up.

baseline metric to determine the presence of MTA and found all subjects to be below this radiographic threshold at the time of final follow-up. Analyzing the percentage of SA reduction may also provide valuable insights as we further our understanding of MTA deformity correction. We also observed that the use of the novel PL measurement accurately predicted the baseline presence of MTA and correlated with its absence

at the time of final follow-up in the majority of subjects. These emerging measures for MTA assessment may help reshape traditional thoughts and lay the groundwork for creating a diagnostic algorithm that determines the optimal timing for MTA correction.

Limitations present in our study include those inherent with retrospective data collection. Radiographic evaluation bias exists in all studies, and we attempted to control for this by having the films read

and compared by board certified foot and ankle surgeons. Foot position can also affect the measured radiographic angular relationships and produce inaccurate measurements as the two-dimensional images produced are based on the beam projection angle. To control for this, it is the practice of the authors to take full weight bearing radiographic views in a typical angle and base of gait with each foot radiographed individually. Weight-bearing 3D computed tomography may have provided a more comprehensive analysis of osseous relationships, but it was not readily available at the time of the index procedure for a large segment of our cohort [35]. We are currently embarking on a long-term prospective multicenter study to understand the effectiveness of the technique and determine patient reported outcomes.

Disclosure of financial interest

J.P. McAleer, P. Dayton, W.T. DeCarbo and D.J. Hatch receive royalties for intellectual property from Treace Medical Concepts, Inc.

Declaration of competing interest

The authors declare the following financial interests/personal relationships which may be considered as potential competing interests

J.P. McAleer, P. Dayton, M. Dayton, W.T. DeCarbo, D. Kile, and D.J. Hatch report relationships with Treace Medical Concepts Inc that include: consulting and advisory fees.

Funding Acknowledgement

This study was funded by a grant from Treace Medical Concepts, Ponte Vedra, FL. Funding was used for direct costs to administer the survey, statistical analysis, IRB oversight and services. No practice or personal income were obtained as part of this study.

Supplementary Materials

Supplementary material associated with this article can be found in the online version at <https://doi.org/10.1053/j.jfas.2025.03.001>.

References

- [1] Aiyer A, Shub J, Shariff R, Ying L, Myerson M. Radiographic recurrence of deformity after Hallux Valgus surgery in patients with metatarsus adductus. *Foot Ankle Int* 2016;37(2):165–71.
- [2] Peabody CW, Muro F. Congenital Metatarsus Varus. *JBJS* 1933;15(1):171.
- [3] Knight RA. Developmental deformities of the lower extremities. *J Bone Joint Surg Am* 1954;36-A(3):521–7. *passim*.
- [4] Harley BD, Fritzhand AJ, Little JM, Little ER, Nunan PJ. Abductory midfoot osteotomy procedure for metatarsus adductus. *J Foot Ankle Surg* 1995;34(2):153–62.
- [5] Conti MS, Caolo KC, Ellis SJ, Cody EA. Radiographic and clinical outcomes of Hallux Valgus and Metatarsus Adductus treated with a modified lapidus procedure. *Foot Ankle Int* 2021;42(1):38–45.
- [6] Shima H, Okuda R, Yasuda T, et al. Operative treatment for Hallux Valgus with moderate to severe metatarsus adductus. *Foot Ankle Int* 2019;40(6):641–7.
- [7] Heyman CH, Herndon CH, Strong JM. Mobilization of the tarsometatarsal and intermetatarsal joints for the correction of resistant adduction of the fore part of the foot in congenital club-foot or congenital metatarsus varus. *JBJS* 1958;40(2):299.
- [8] Viehweger E, Jacquemier M, Launay F, Giusiano B, Bollini G. First cuneiform osteotomy alters hindfoot architecture. *Clin Orthop Relat Res* 2005;441:356–65.
- [9] Krakowsky D, Leveille DW, Hansen MP. Treatment of metatarsus adductus in adults with first metatarsal cuneiform arthrodesis and closing osteotomy of the cuboid. *Tech Foot Ankle Surg* 2010;9(2):64–7.
- [10] Lalevee M, de Cesar Netto C, ReSurg Boubli D, Coillard JY. Recurrence rates with longer-term follow-up after Hallux Valgus surgical treatment with distal metatarsal osteotomies: a systematic review and meta-analysis. *Foot Ankle Int* 2023;44(3):210–22.
- [11] Aiyer A, Myerson M. Management of hallux valgus deformity in patients with severe metatarsus adductus: a proposed treatment algorithm. In: *Orthopaedic Proceedings*. Vol 98. The British Editorial Society of Bone & Joint Surgery; 2016. 26–26.
- [12] Dawoodi AIS, Perera A. Reliability of metatarsus adductus angle and correlation with hallux valgus. *Foot Ankle Surg* 2012;18(3):180–6.
- [13] Yu GV, DiNapoli DR. Surgical management of hallux abductovalgus with concomitant metatarsus adductus. In: McGlamry ED, editor. *Reconstructive Surgery of the Foot and Leg*. 87. Tucker, Georgia, USA: Update Podiatry Institute; 2013. p. 262–8.
- [14] Smith WB, Santrock RD, Hatch DJ, Dayton P. Intraoperative multiplanar alignment system to guide triplanar correction of Hallux Valgus deformity. *Tech Foot Ankle Surg* 2017;16(4):175.
- [15] McAleer JP, Dayton P, DeCarbo WT, et al. A systematic approach to the surgical correction of combined Hallux valgus and metatarsus adductus deformities. *J Foot Ankle Surg* 2021;60(5):1048–53.
- [16] Kilmartin TE, Flintham C. Hallux Valgus surgery: a simple method for evaluating the first-Second intermetatarsal angle in the presence of metatarsus adductus. *J Foot Ankle Surg* 2003;42(3):165–6.
- [17] Standard SC, Herzenberg JE, Conway JD, Lamm BM, Siddiqui NA. Foot and ankle: normal alignment. *The Art of Limb Alignment*. 3rd 2014. p. 123–4.
- [18] Perren S. Evolution of the internal fixation of long bone fractures. *J Bone Joint Surg B* 2002;84-B(8):1093–110.
- [19] Sgarlato T.E. *Compendium of Podiatric Biomechanics*. Vol 1971. California College of Podiatric Medicine; San Francisco.
- [20] McAleer JP, DeCarbo WT, Santrock RD, Hatch DJ, Dayton P, Smith WB. A simplified preoperative radiographic assessment for metatarsus adductus associated with Hallux Valgus. *Foot Ankle Spec* 2024;193. Published online April 23.
- [21] Hatch DJ, Smith A, Fowler T. Radiographic relevance of the distal medial cuneiform angle in Hallux Valgus assessment. *J Foot Ankle Surg* 2016;55(1):85–9.
- [22] Hardy RH, Clapham CR. J. OBSERVATIONS on Hallux Valgus. *Bone Joint J* 1951; 33-B(3):376–91.
- [23] Mani SB, Lloyd EW, MacMahon A, Roberts MM, Levine DS, Ellis SJ. Modified lapidus procedure with joint compression, meticulous surface preparation, and shear-strain-relieved bone graft yields low nonunion rate. *HSS J* 2015;11(3):243–8.
- [24] Vaida J, Ray JJ, Shackelford TL, et al. Effect on foot width with triplanar tarsometatarsal arthrodesis for Hallux Valgus. *Foot Ankle Orthop* 2020;5(3):247.
- [25] Banks AS, Downey MS, Martin DE. Metatarsus adductus and allied disorders. In: Vickers NS, editor. *McGlamry's Comprehensive Textbook of Foot and Ankle Surgery*. 3rd Edition. Philadelphia, Pennsylvania, USA: Lippincott Williams & Wilkins; 2001. p. 920–1.
- [26] Ouzounian TJ, Shereff MJ. In vitro determination of midfoot motion. *Foot Ankle* 1989;10(3):140–6.
- [27] Kurup H, Vasukutty N. Midfoot arthritis- current concepts review. *J Clin Orthop Trauma* 2020;11(3):399–405.
- [28] Shibuya N, Jasper J, Peterson B, Sessions J, Jupiter DC. Relationships between first metatarsal and sesamoid positions and other clinically relevant parameters for Hallux Valgus surgery. *J Foot Ankle Surg* 2019;58(6):1095–9.
- [29] Okuda R, Kinoshita M, Yasuda T, Jotoku T, Kitano N, Shima H. Postoperative incomplete reduction of the sesamoids as a risk factor for recurrence of hallux valgus. *J Bone Joint Surg Am* 2009;91(7):1637–45.
- [30] Schneider W, Knahr K. Surgery for hallux valgus. The expectations of patients and surgeons. *Int Orthop* 2001;25(6):382–5.
- [31] Saro C, Jensen I, Lindgren U, Felländer-Tsai L. Quality-of-life outcome after hallux valgus surgery. *Qual Life Res* 2007;16(5):731–8.
- [32] Tai CC, Ridgeway S, Ramachandran M, Ng VA, Devic N, Singh D. Patient expectations for Hallux Valgus surgery. *J Orthop. Surg.* 2008;16(1):91–5.
- [33] Martinelli N, Marinozzi A, Cancilleri F, Denaro V. Hallux valgus correction in a patient with metatarsus adductus with multiple distal oblique osteotomies. *J Am Podiatr Med Assoc* 2010;100(3):204–8.
- [34] Aiyer AA, Shariff R, Ying L, Shub J, Myerson MS. Prevalence of metatarsus adductus in patients undergoing hallux valgus surgery. *Foot Ankle Int* 2014;35(12):1292–7.
- [35] Lintz F, Beaudet P, Richardi G, Brilhault J. Weight-bearing CT in foot and ankle pathology. *Orthop Traumatol Surg Res* 2021;107(1S):102772.